



PATIENT PRESENTING CLINICAL SIGNS

Willy Seel Gerrick Had eye enucleation last Aug 2024, socket filled with purulent debris this summer, explore showed retained piece of suture. Overnight, eye socket ruptured again and hemorrhagic fluid draining from socket. CT to determine surgical options.

SPECIES

Canine

Abnormal PE/Chem/CBC/UA Results: NAF

COMPUTED TOMOGRAPHIC STUDY OF THE HEAD

BREED

Shepherd Mix

Plain and post contrast studies are available for review. Patient has a history of enucleation of the left eye.

COMPUTED TOMOGRAPHIC FINDINGS

SEX

MN

Marked destructive chronic rhinosinusitis affecting the dorsal and caudal nasal cavities and both frontal sinuses is seen. There is severe turbinate destruction and irregular bone destruction. The cribriform region is spared with areas of reactive hyperostosis and extensive mucosal thickening.

AGE

1yr

The nasal maxillary and frontal bones show areas of distortion and asymmetry consistent with prior traumatic injury (unreported) or chronic inflammatory remodeling. Acute fractures are not identified.

INTERPRETED BY

Nele Eley (Ondreka),
DVM Dr. med. vet.,
DipECVDI

Medial soft tissue swelling is seen in the left orbit without discrete rim enhancing abscess cavity being present. A small amount of soft tissue emphysema is present which may represent local puncture or recent rupture of the socket clinically noted (air tracking from nasal cavity through areas of bone loss or gas forming infection both being considered less likely). No infraorbital foreign material is visualized.

Extensive soft tissue swelling is seen lateral to the left caudal maxilla centered over tooth positions 208 and 209. Severe periodontal ligament space widening and periapical lucency of both 208 and 209 are present. Possible early cortical breakthrough of the alveolar bone in the region is noted as well.

HOSPITAL NAME

Bridgwater Veterinary
Hospital

The bilateral submandibular and medial retropharyngeal lymph nodes are mildly enlarged compatible with reactive lymphadenitis.

The brain parenchyma presents within normal limits at this time.

REFERRING VET

Dr. K. Choptain

COMPUTED TOMOGRAPHIC DIAGNOSIS

- Severe destructive rhinosinusitis most consistent with chronic fungal rhinitis
- Left tooth root abscesses of 208 and 209 with regional cellulitis
- Soft tissue swelling of the left orbital region without discrete abscess cavity
- Mild emphysema possibly related to socket rupture or air tracking
- Regional reactive lymphadenitis
- Chronic bone remodeling and distortion of facial bones

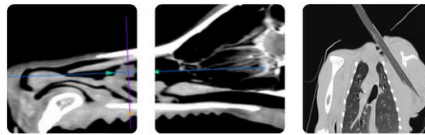
INVOICE

23208

DATE

12/10/2025

INTERPRETATION OF FINDINGS & FURTHER RECOMMENDATIONS



PATIENT

Willy Seel Gerrick

The patient has two significant and likely concurrent sources of ongoing infection. One is the caudal maxillary tooth root abscesses of 208 and 209 and two, destructive rhinosinusitis fungal most likely, bacterial less likely.

SPECIES

Canine

Currently there is no well-formed orbital abscess notable however diffuse soft tissue inflammation appears to be present both within the left orbit as well as lateral to the caudal left maxilla.

BREED

Shepherd Mix

SEX

MN

AGE

1yr

INTERPRETED BY

Nele Eley (Ondreka),
DVM Dr. med. vet.,
DipECVDI

HOSPITAL NAME

Bridgwater Veterinary
Hospital

REFERRING VET

Dr. K. Choptain

INVOICE

23208

DATE

12/10/2025



PATIENT

Willy Seel Gerrick

SPECIES

Canine

BREED

Shepherd Mix

SEX

MN

AGE

1yr

INTERPRETED BY

Nele Eley (Ondreka),
DVM Dr. med. vet.,
DipECVDI

HOSPITAL NAME

Bridgwater Veterinary
Hospital

REFERRING VET

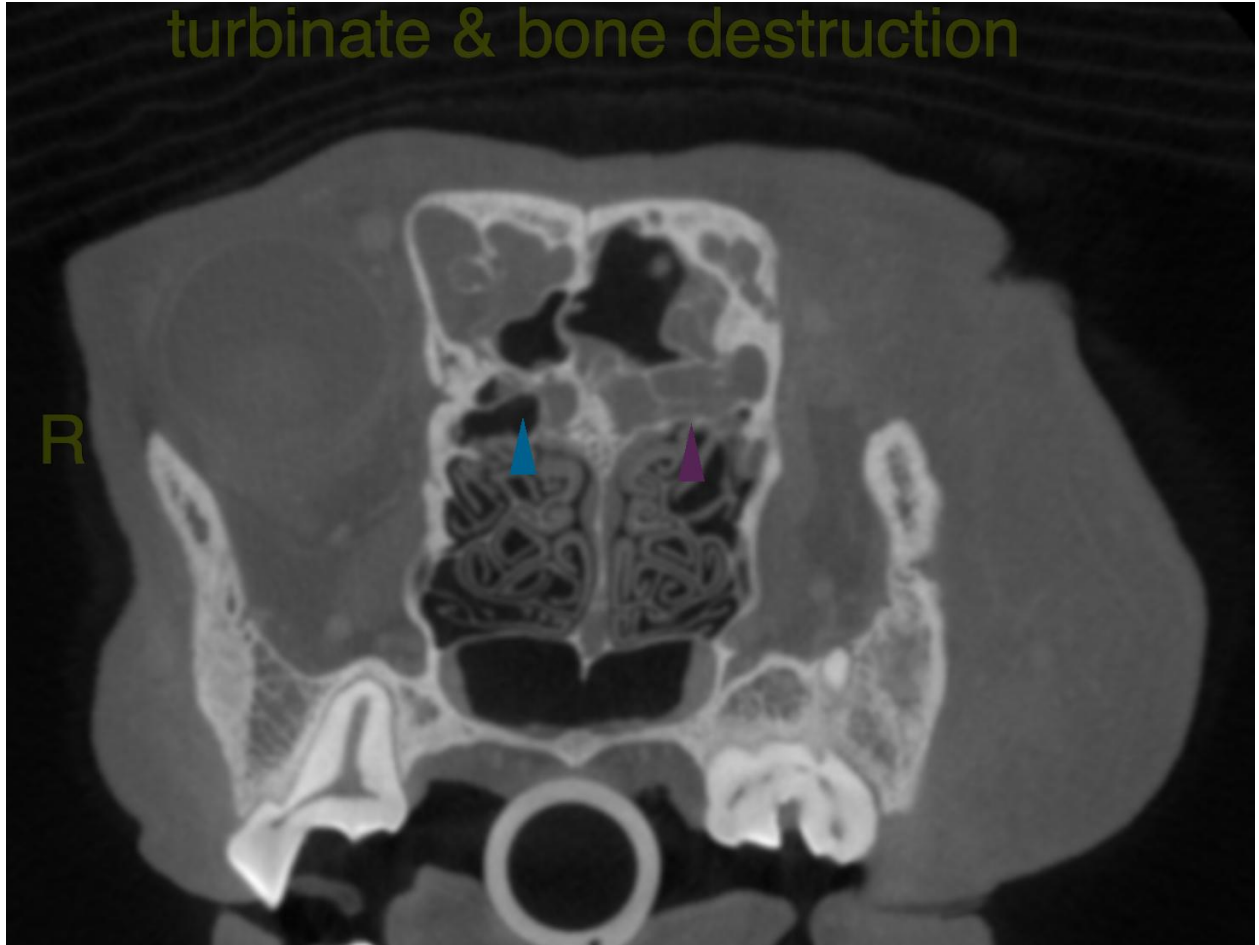
Dr. K. Choptain

INVOICE

23208

DATE

12/10/2025





PATIENT

Willy Seel Gerrick

SPECIES

Canine

BREED

Shepherd Mix

SEX

MN

AGE

1yr

INTERPRETED BY

Nele Eley (Ondreka),
DVM Dr. med. vet.,
DipECVDI

HOSPITAL NAME

Bridgwater Veterinary
Hospital

REFERRING VET

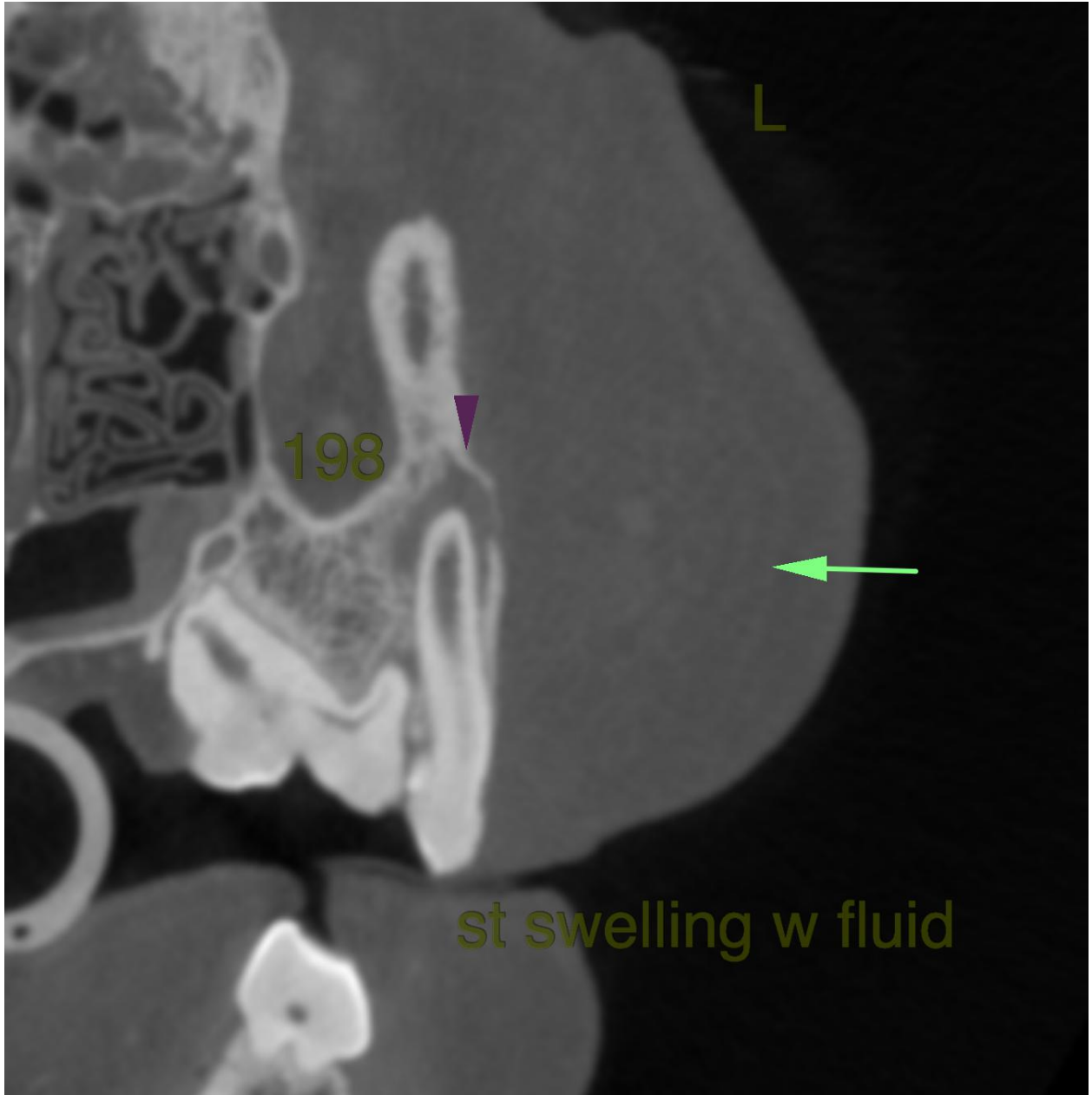
Dr. K. Choptain

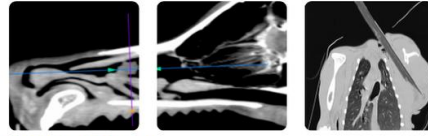
INVOICE

23208

DATE

12/10/2025





PATIENT

Willy Seel Gerrick

SPECIES

Canine

BREED

Shepherd Mix

SEX

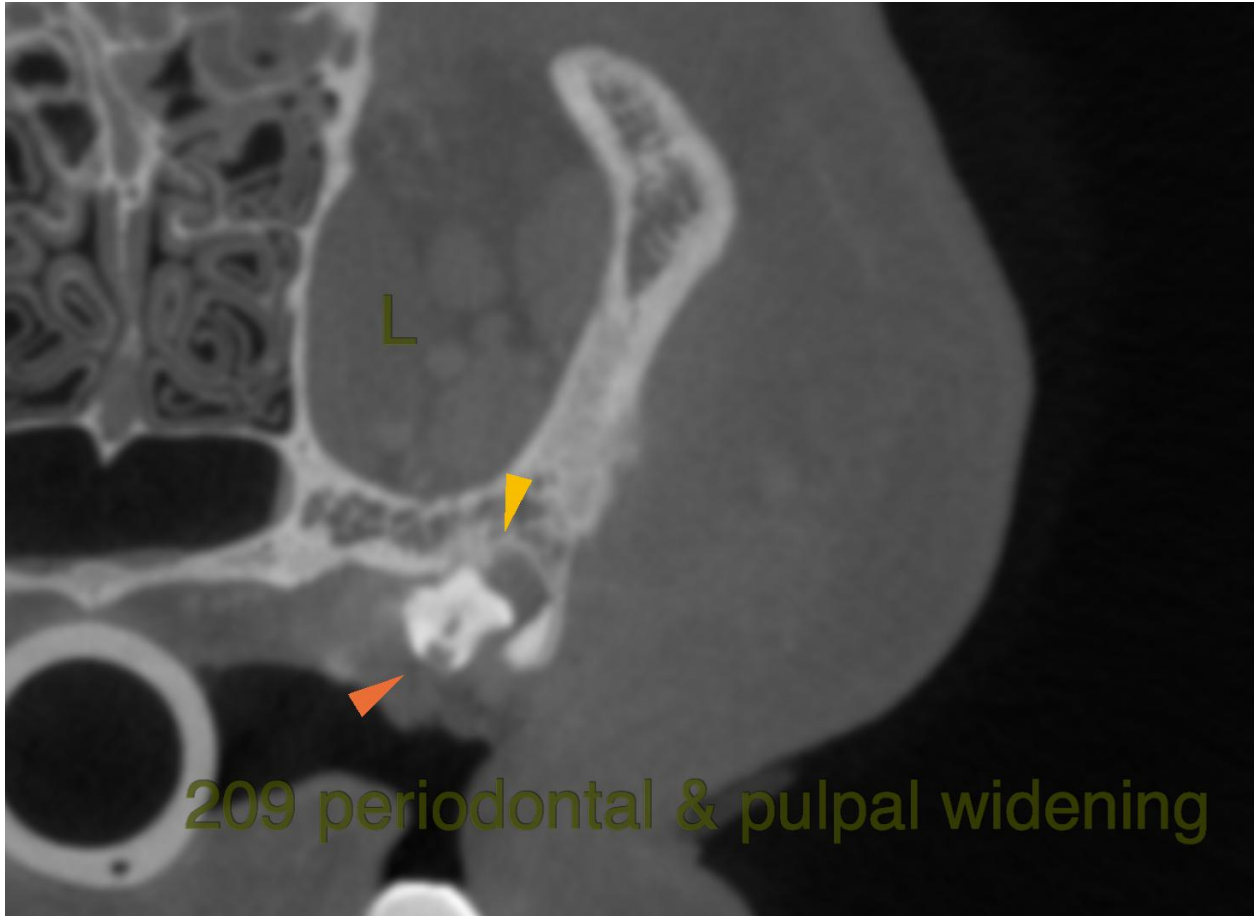
MN

AGE

1yr

INTERPRETED BY

Nele Eley (Ondreka),
DVM Dr. med. vet.,
DipECVDI



HOSPITAL NAME

Bridgwater Veterinary
Hospital

REFERRING VET

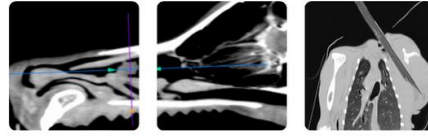
Dr. K. Choptain

INVOICE

23208

DATE

12/10/2025



PATIENT

Willy Seel Gerrick

The information and recommendations provided are based on the images presented by the referring veterinarian. No evaluation can be communicated regarding pathology that was not visible in the image/video clips provided.

SPECIES

Canine

Thank you for this referral. If the clinical or image interpretation does not parallel your findings or if I can be of any further assistance please contact me.

BREED

Shepherd Mix

Nele Eley (Ondreka), DVM, Dr. med. vet., DipECVDI
European Specialist in Veterinary Diagnostic Imaging, Cert. Radiology,
Senior lecturer University of Giessen/Germany, Veterinary Faculty, Department of Radiology.
info@sonopath.com

SEX

MN

AGE

1yr

INTERPRETED BY

Nele Eley (Ondreka),
DVM Dr. med. vet.,
DipECVDI

HOSPITAL NAME

Bridgwater Veterinary
Hospital

REFERRING VET

Dr. K. Choptain

INVOICE

23208

DATE

12/10/2025